



PATIENT

Rico Mickle

SPECIES

Canine

BREED

Japanese Chin

SEX

MI

AGE

2015

WEIGHT

9.7lbs

INTERPRETED BY

Maggie Machen Lamy,
DVM, DACVIM
(Cardiology)

HOSPITAL NAME

Northwind AH

REFERRING VET

Dr. Cross

INVOICE

23467

DATE

4/6/22

PRESENTING CLINICAL SIGNS

History: Presented to the ER 4/4/22 for 2 weeks of labored breathing. Lethargic with neck stretching. P has intermittent honking cough, collapse trachea cough. Grade 3/6 murmur noted on exam 3/31/22. P eating/drinking normal, no other concerns. Current medications (from ER): Gabapentin suspension, Pimobendan, Hydrocodone suspension, Cerenia, Butorphanol and Furosemide. BP 160mmHg. Sedation used: Not required to complete full diagnostic ultrasound. Pertinent previous ultrasound results: No previous. STAT: Requested. Imaging performed by: Stephanie Pearce RDCS, RVT.

RADIOGRAPHIC FINDINGS *NOTE: Images submitted for supplemental information only.

Mild cardiomegaly. Mixed pulmonary pattern.

ECHOCARDIOGRAM FINDINGS

2D, m-mode, color flow and doppler imaging is available. Diffuse thickening of mitral valve leaflets with mild prolapse into the left atrial lumen. Moderate eccentric mitral regurgitation with mild left atrial dilation. Normal MR velocity. Mild LV dilation with adequate myocardial function. The tricuspid valve appears mildly thickened with mild tricuspid regurgitation. Normal velocity. Normal right atrial and ventricular diameter and morphology indicating no overt evidence of pulmonary arterial hypertension. The pulmonic and aortic valves are normal in morphology and mobility. Normal pulmonic and aortic outflow velocities with laminar flow. No obvious aortic or pulmonic insufficiency. No pericardial or pleural effusion noted. No obvious cardiac masses.

CARDIAC CHART

CANINE CARDIAC PARAMETERS	MR VMAX (m/s)	TR VMAX (m/s)	LA/AO (Boon method)	LA/AO (Heart Base; Swe)	FS (%)	EF (%)	EPSS (cm)
NORMAL PARAMETER	4.5-5.5	<2.7	1.3	<1.6	28-40	40-100	<0.6
PATIENT	5.7	2.7	NM	1.5	54	86	NM
CANINE CARDIAC PARAMETERS	HR (BPM)	AV VMAX (m/s)	PV MAX (m/s)	BODY WEIGHT (kg)	LA 2D short axis Base view (cm)	LVIDd Avg; 2D and m-mode short axis (cm)	LVIDs Avg; 2D and m-mode short axis (cm)
NORMAL PARAMETER	50-100	0.7-1.7	0.7-1.6	BELOW	BELOW	BELOW	BELOW
PATIENT	130	1.1	0.72	4.4	1.8	3.0	1.4
*Normal chamber parameters expressed as a mean value (SD)				3	1.27 (5.3)	2.46 (2.46)	1.36 (5.5)
BODY WEIGHT DEPENDENT PARAMETERS				5	1.40 (4.5)	2.74 (5.2)	1.60 (4.7)
<i>*Note: All measurements based upon multi-modal images and methods. An average value is reported.</i>				10	1.50 (3.8)	3.27 (3.5)	2.06 (3.1)
				15	1.83 (2.0)	3.71 (2.4)	2.43 (2.1)
				20	2.02 (1.9)	4.14 (2.2)	2.80 (2.0)
				25	2.18 (2.4)	4.48 (2.9)	3.10 (2.5)
				30	2.33 (3.3)	4.83 (3.9)	3.39 (3.4)
				35	2.48 (4.3)	5.17 (5.0)	3.69 (4.5)
				40	2.62 (5.2)	5.48 (6.1)	3.96 (5.4)
				50	2.88 (7.1)	6.07 (8.3)	4.46 (7.4)

Adapted from June Boon, Veterinary Echocardiography, 1998
Rishniw M and Hollis NE, J Vet Intern Med 2000; 14:429-435
Hansson et al, Vet Rad and Ultrasound 2002
Bonagura et al. Echocardiography: principles of interpretation, Vet Clin North Am 15:1177, 1995

INTERPRETATION OF THE FINDINGS & FURTHER RECOMMENDATIONS

Chronic degenerative valve disease causing moderate mitral and mild tricuspid regurgitation. Mild left atrial enlargement indicates the current risk for complication is low. No concurrent issues such as systolic dysfunction or pulmonary hypertension are noted in this study.

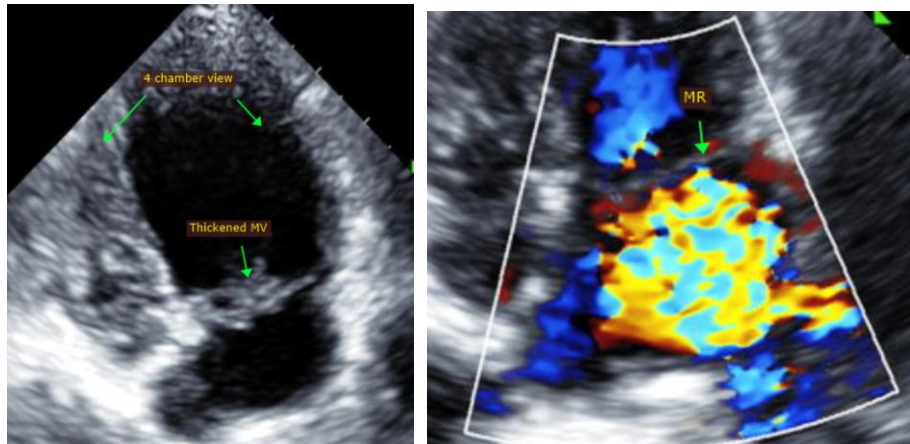
Given these findings, dyspnea/cough is more likely to be primary respiratory in origin with CHF considered unlikely. If there is any debate on this diagnosis, a radiologist review of the films is recommended as a second opinion. CHF is radiographic diagnosis that can only be supported by severe disease identified on ultrasound (not seen here). Treatment of pulmonary disease may include oxygen support, broad-spectrum pulmonary antibiotics, theophylline, anti-inflammatory prednisone, etc. Given the chronic respiratory disease can lead to pulmonary hypertension over time. Monitor for signs of this development including exertional collapse or dyspnea.

Given these findings, cardiac medications are not clearly indicated. Assessment of progression in the future will help predict long term prognosis, which is highly variable at this stage (B1). Omega fatty acid supplementation and mild salt restriction may be of some long term benefit. Monitor for development of a cough, labored breathing, exercise intolerance or collapse episodes.

Anesthetic risk is considered mild if needed. Cardiac protective drug choices (opioid/benzodiazepine premedication, propofol or alfaxalone induction, isoflurane gas) are recommended. Pre-oxygenate for 5-10 minutes prior to induction. Monitor for arrhythmias, hypotension, and hypoxia both intra and post-operatively and intervene as necessary. Mild IV fluid restriction is recommended to avoid fluid overload. Avoid heart rate stimulating drugs such as atropine unless clinically indicated.

Plan: Consider Radiologist review of the films. Consider further respiratory work up/treatment as discussed. Recommend conservative monitoring with a recheck echocardiogram in 6 months, sooner if any development of clinical signs.

IMAGES



The information and recommendations provided are based on the images presented by the referring veterinarian. No evaluation can be communicated regarding pathology that was not visible in the image/video clips provided.

Thank you for this referral. This report was generated using transcription software, and minor dictation errors may be present. If the clinical or image interpretation does not parallel your findings or if I can be of any further assistance please contact me.

Maggie Machen Lamy, DVM
Diplomate of the American College of Veterinary Internal Medicine (Cardiology)
info@sonopath.com